

Direct Veneers Just Got a Whole Lot Easier



By Sigal Jacobson, DMD

Many of us still remember the past generation composites. Reproduction of the natural characteristics of a tooth was difficult because of the lack of available shades as well as the less-than-

ideal physical qualities of the materials. Since that time, various aesthetic composite resin materials have been introduced that possess exceptional color characteristics and improved physical qualities.

Given a composite's advantages, why is direct composite veneering of teeth so frequently overlooked in favor of the porcelain veneer option? One would first assume that the artistic ability needed to reproduce the correct contour, shape, and shine would pose a major deterrent in participating in the process. Dentists will often state that composite veneering is time-consuming and cost-ineffective, with results that are not predictable and sometimes disappointing.

This author is happy to report that Dental Art innovations, an Australian company, has recently introduced a unique product called Uvener. The Uvener system is a complete set of translucent templates that allows easy and fast reproduction of anterior tooth anatomy in the form of a composite veneer. The Uvener uses innovative technologies that help the dentist to achieve a refined, anatomically correct, high-gloss restoration in a fraction of the time than if done freehand. Results are both reproducible and predictable. The operator needs to press the clear template onto the composite that has been applied to the prepared tooth, cure, and remove the Uvener template. The result will be a shiny and anatomically correct tooth surface. The Uvener kit includes all anterior teeth and premolars in both upper and lower arches. Two sizes, large and universal, are provided, according to research on smile design sizes and proportions. The Uvener is made from a medical-grade translucent plastic that does not adhere to the composite resin and is both reusable and autoclavable.

TECHNIQUE

This young woman was embarrassed to show her teeth. Tooth No. 10 is an implant crown restoration with poor match to the rest of the dentition (Figure 1).

The treatment option she was offered by another dentist to get satisfactory cosmetic results was a porcelain work on all 4 incisors. This approach proved to be beyond her budget, since her resources were diminished by her implant treatment. The treatment plan offered in this case by the dentist was 3 composites veneers on teeth Nos. 9, 8, and 7 with Uvener system.

The correct template is chosen (Figure 2). Note

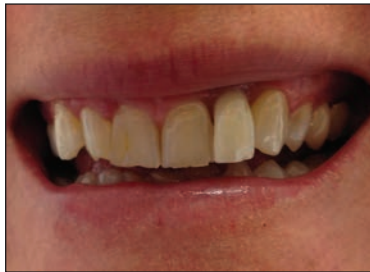

Figure 1.

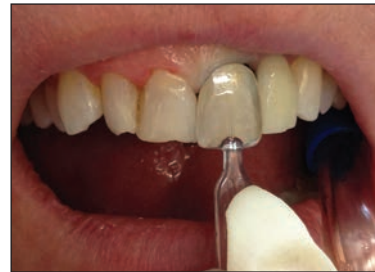

Figure 2.

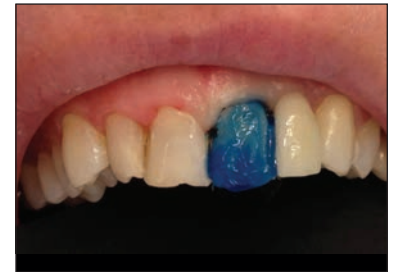

Figure 3.

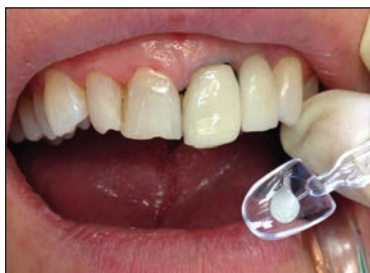

Figure 4.

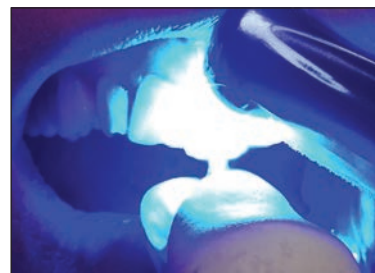


Figure 5.

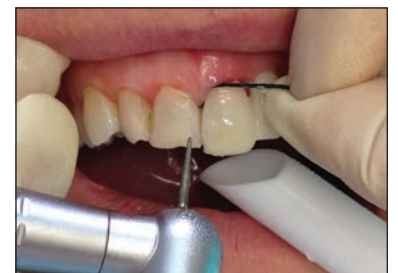

Figure 6.

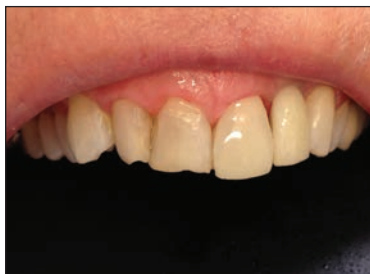

Figure 7.

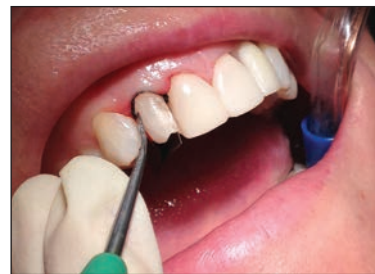

Figure 8.

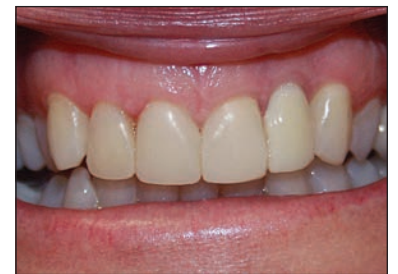

Figure 9.

that its size and shape corresponds nicely to the tooth to be veneered, No. 9. The teeth to be veneered required little preparation as they are retroclined.

After the insertion of retraction cord and sectional matrixes, the tooth was etched for 15 seconds (Figure 3).

The tooth is sprayed with water for 5 seconds and gently dried. The adhesive system is then applied and cured for 20 seconds. (This was done with VOCO America's Futurabond U.)

A composite resin is then applied to the tooth labial surface without curing yet. (This was done with Danville Materials' ZNano. Figure 4).

A small amount of flowable composite is applied into the template by using VOCO America's GrandioSO and pressed onto the uncured composite that has been laid on the tooth. Excess is removed from the periphery using a probe.

Then light cure throughout the template while pressing for 30 seconds by using Ultradent Products' VALO LED curing light (Figure 5). The template is then removed.

Retraction cord and separators are also removed. Residual excess is cleaned from the periphery with flame-finishing diamond burs (Figure 6).

The Uvener template will generate the shine

(also assisted by the blocking the oxygen-inhibiting layer) and the correct anatomy of the tooth (Figure 7). The same procedure was repeated for teeth Nos. 7 and 8 (Figure 8).

Three composite veneers with the Uvener system were completed on 3 teeth—Nos. 7, 8, and 9—in less than an hour. Everyone was very excited by the results (Figure 9).

CONCLUSION

By combining today's improved composite materials with the Uvener's innovative and unique delivery technique, dentists can now create smile solutions that were not possible before. The result is conservative, functional restorations with excellent aesthetics in a fraction of the time that it previously took.

For additional information, call Dental Art innovations at (888) 771-0479 or visit uvener.com.

Dr. Jacobson is the inventor of the Uvener system. She is based in Melbourne, Australia, and has run her private clinic for more than 19 years with a focus on aesthetic dentistry. She lectures internationally about the Uvener system as well as methods to increase acceptance rate in cosmetic cases, sell treatment plans, and raise practice profitability.