Optimizing the composite resin stratification technique with prefabricated templates: a case report

Andrés Dávila-Sánchez, DDS, MSc, PhD
Operative Dentistry and Biomaterials, Universidad San Francisco de Quito, Ecuador

Camilo Pulido, DDS, MSc, PhD
Professor, Department of Oral Health, Universidad Nacional de Colombia, Colombia

Andrés Fernando Montenegro-Arana, DDS, MSc, PhD
Graduate School, Universidade Estadual de Ponta Grossa, Brazil

Gislaine Martins, DDS, MSc, PhD
Postdoctoral Student, Pontificia Universidade Católica do Paraná (PUC-PR), Brazil

Cesar Augusto Galvão Arrais, DDS, MSc, PhD
Professor, Operative Dentistry and Biomaterials, Universidade Estadual de Ponta Grossa, Brazil

Alessandro Loguercio, DDS, MSc, PhD
Professor, Operative Dentistry and Biomaterials, Universidade Estadual de Ponta Grossa, Brazil

Correspondence to: Dr Andres Davila-Sanchez
Operative Dentistry and Biomaterials, Universidad San Francisco de Quito, Diego de Robles y Av, Interoceánica, Quito, 170901, Ecuador; Tel: +593 297 1700; Email: cadavilas@usfq.edu.ec

Abstract

Direct freehand veneers with composite resin (CR) require high clinician ability and a long chair time. Although CR restorations remain the most-used technique for meeting high esthetic demands, and new technologies mean that materials are nowadays more similar to tooth structure, layering techniques for natural results are still considered difficult to achieve. Through advances in adhesive dentistry, systems of prefabricated veneers using conventional techniques have been launched onto the market as an option for the clinician. This case report presents complete step-by-step descriptions of two techniques using prefabricated templates for directly built-up veneers. Both maxillary lateral incisors were simultaneously reconstructed with direct CR veneers with different layering techniques to achieve esthetic results in a shorter chair time. Simple stratification techniques using prefabricated templates may allow clinicians to optimize both time and clinical outcome while obtaining predictable results.

(Int J Esthet Dent 2019;14:2–14)

Introduction

The growing access to media has had an impact on patients' demand for esthetic dental procedures. Tin-Oo et al[1] showed that most patients are not satisfied with their dental appearance. Patients consider color changes,[1,2] shape, structural abnormalities,[2,3] and the position of anterior teeth to be important esthetic issues.[2] As a result, practitioners are increasingly performing esthetic procedures to meet their patients' needs.

In the past, most treatments involving dental esthetics comprised invasive techniques such as full-crown preparations. With the introduction of adhesive dentistry and the concept of minimally invasive dentistry, less-invasive techniques such as tooth whitening,[4] microabrasion,[5] and direct restorations[6] have become reliable options with predictable results. In some situations, indirect thin ceramic veneers are indicated.[7] This procedure has been considered the gold standard for building up the shape and color of anterior teeth when it is impossible to achieve satisfactory results with other less-invasive procedures.[8] The high success rate of these restorations is related to the inherent properties of ceramic such as optimal esthetics, excellent biomechanical behavior after cementation, and the maintenance of gloss and texture over time.[9] However, the high cost of ceramic veneers and the need for many clinical steps make this procedure very expensive and thus limit its general use.

Due to the need to reduce the costs of restorative procedures, direct veneers with composite resins (CRs) are considered a good option compared with ceramic veneers.[10-13] Nowadays, CRs are the most-used material for esthetic purposes[14] due to their very good color matching, polishability, and the possibility of performing more conservative preparations for material placement.[11] However, the long-term clinical performance of direct composite veneers should be taken into account when deciding which technique to use, and this procedure is indicated only in teeth with margins in enamel.[12,13] In addition, when compared with indirect restorations, direct composite veneers are highly dependent on the operator's skills, as a combination of knowledge of dental morphology and layering techniques is required to obtain satisfactory, natural-looking results. Thus, the increased chair time may mean that direct composite veneers are not suitable for all clinicians.

Due to these disadvantages, the use of minimally invasive templates is an option to help clinicians produce direct composite veneers based on the esthetic reconstruction of the vestibular dental anatomy. This is achieved in three steps: the filling of the transparent templates with composite resin; the application and adaptation of the templates to the tooth surface; and light curing.

Although predictable shape and symmetry can be obtained with these systems, the manufacturers' instructions recommend the use of monolayer restorations because they suggest the application of a single layer of CR after the bonded procedures to obtain the final restoration. This means there is a lack of descriptive techniques for challenging situations in anterior teeth, where restorative procedures with varying shades along the tooth cannot be accomplished with monolayer techniques, so these systems may not provide the optimal esthetic results expected by the clinician and patient. This could be one of the reasons why clinicians are discouraged from using prefabricated templates, as they believe their use and outcome might be limited. Thus, the objective of this clinical report was to present the use of transparent templates with two clinical techniques to provide polychromatic, esthetic anterior CR veneers in a shorter clinical chair time.

Fig 1 (a) Initial situation. Lateral incisors with chromatic and shape alterations. (b) Intraoral view of the maxillary left lateral incisor. (c) Intraoral view of the maxillary right lateral incisor.

Case report

A 21-year-old female patient was referred to the Restorative Dental Clinic of the Brazilian Dental Association – Ponta Grossa (ABO-PG). Her main complaint was the discoloration, shape, and color mismatch of her maxillary lateral incisors (Fig 1a). Dental at-home bleaching with 10% carbamide peroxide for 2 weeks was previously performed to obtain a substrate shade as similar as possible to that of the adjacent teeth to facilitate the stratification of the veneers. Anamnesis, a clinical examination, and radiographs of the patient's anterior teeth were performed to verify the periodontal and endodontic condition of the maxillary right and left lateral incisors that presented darkened crowns (Fig 1b and c).

Given her age and the characteristics of her maxillary lateral incisors, it was decided to perform direct CR veneers using Uveneer templates (Ultradent) on the lateral incisors, with the aim of improving the desired tooth shade and tooth shape as well as harmony between the anterior teeth.

Tooth preparation

To prepare the teeth, a retraction cord (Ultrapack No. 000; Ultradent) was used to promote gingival retraction (Fig 2a). The initial and minimally invasive preparation was performed with a fine-grit diamond bur (No. 2235; KG Sorensen) (Fig 2b) to delimit the tooth contour with a slightly subgingival bevel, so that a finishing line was created at the cervical and proximal regions.

Subsequently, the labial surface was reduced by approximately 0.3 mm in the cervical region, 0.3 mm in the middle third, and 0.3 mm in the incisal third (Fig 2c) with fine (No. 2135 F) and extra-fine (No. 2135 FF) truncated cone diamond burs (KG Sorensen) in a multiplier contra-angle (NSK 1:5 Titanium; NSK). Polishing was then performed using abrasive discs (Sof-Lex; 3M ESPE).

Proof and installation of templates

The Uveneer kit consists of a complete set of 32 translucent templates (16 maxillary and 16 mandibular) divided into groups of

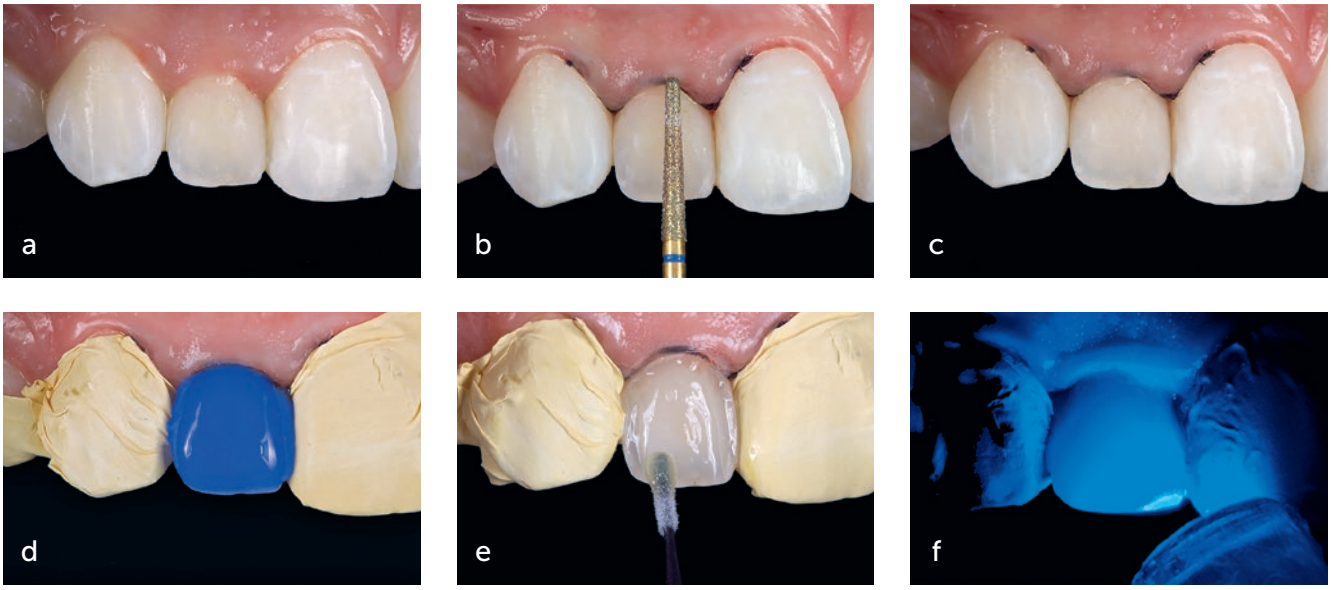

Fig 2 Sequence of preparation and adhesive protocol on the maxillary right lateral incisor. (a) Gingival clearance with retractor cord. (b) Minimally invasive bur preparation. (c) Finished preparation. (d) Application of phosphoric acid. (e) Application of universal adhesive on the enamel surface. (f) Photoactivation of the adhesive on the tooth.

eight templates (bicuspid to bicuspid). They are also grouped according to size: large (L) or medium (M). First, we selected the template that corresponded to the teeth being restored. Then, we checked the handle of the template for the corresponding tooth position, size, and arch.

The prefabricated template size was chosen based on the comparison with the lateral incisors, and the templates were placed on each prepared tooth surface for adjustment before acid etching to ensure the correct tooth inclination, embracement, and final position based on the location of the gingival zenith. This was done in order to determine the correct tooth axis.

Adhesive procedures

The enamel surface was etched with 35% phosphoric acid gel (Ultra-Etch; Ultradent) for 15 s (Fig 2d), water rinsed for 30 s, and subsequently air dried for 5 s. A universal adhesive (Peak Universal; Ultradent) was gently applied to the enamel surface according to the manufacturer's instructions (Fig 2e), air dried for 5 s, and photoactivated for 20 s (irradiance: 1000 mW/cm^2) (Valo; Ultradent) (Fig 2f).

Technique 1: Stratification of dentin and enamel using prefabricated veneer templates

After the bonding procedure, the template was placed in position on the maxillary right lateral incisor to determine the appropriate size and to check the adaptation at the cervical region. The first layer of A1-shade 'dentin' CR (Vit-l-escence; Ultradent) was applied to the inner surface of the template (size M) to mask the darkened substrate (Fig 3a). The filled template was brought into position, and the resin layer was photoactivated for 20 s (Fig 3b). After removing the template, it was possible to see the CR excess (Fig 3c), which was removed with Sof-Lex discs and a diamond bur with greater granulation to create a rougher surface on the 'dentin' CR layer to allow for the application of a subsequent layer (Fig 3d). The tooth was conditioned with 35% phosphor-

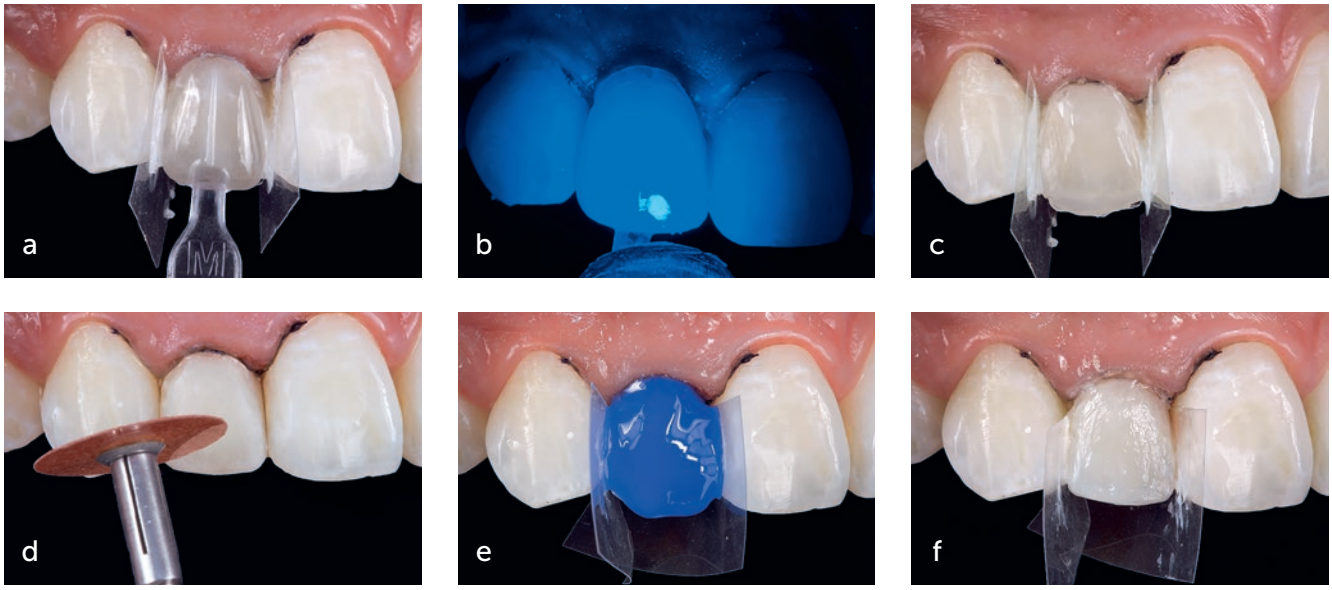

Fig 3 Tooth-restoration sequence for the dentin layer on the maxillary right lateral incisor. (a) Proof and positioning of the prefabricated template. (b) Photoactivation according to the manufacturer's instructions. (c) View of the dentin layer. (d) Excess removal and creation of an irregular surface. (e) Application of phosphoric acid for 1 min to clean the surface. (f) Application of the adhesive onto the dentin layer.

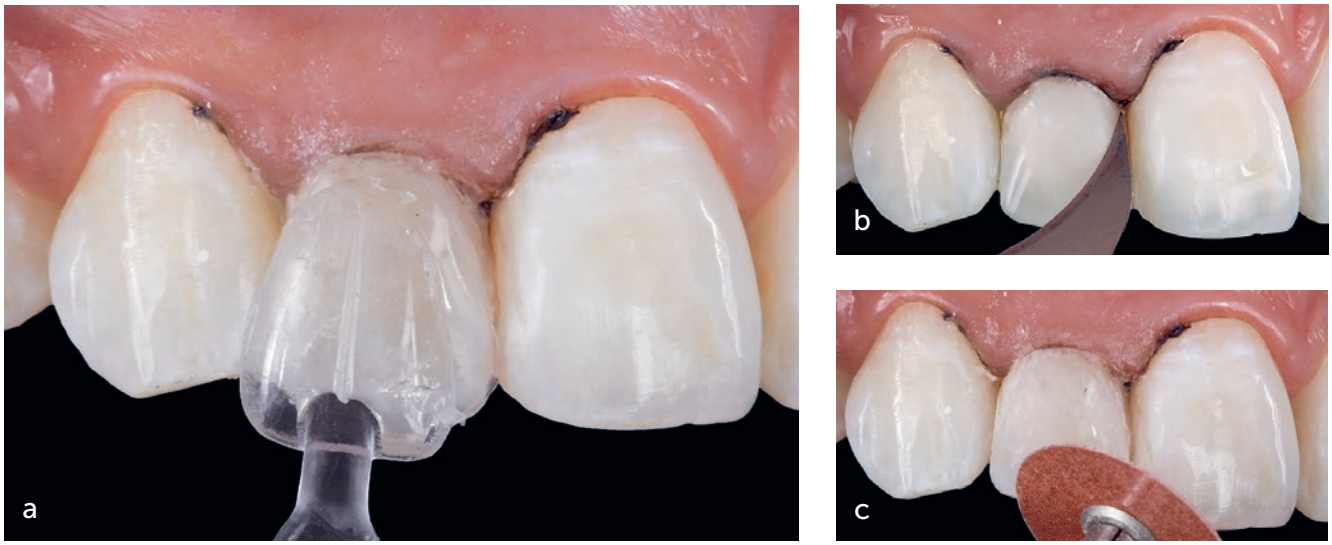

Fig 4 Restoration sequence of the enamel layer on the maxillary right lateral incisor. (a) Proof and positioning of the prefabricated template. (b) Excess removal with a No. 12 scalpel blade. (c) Regularization of the labial surface with sandpaper discs.

ic acid for 1 min, and the bonding agent was applied as described above[15] (Figs 3e and f).

Afterwards, orange pigments were applied to the cervical region, and a blue pigment was applied to the incisal region (Kolor + Plus; Kerr Dental). Likewise, an opaque white pigment (Kolor + Plus) was applied over the opaque halo region. The template (size L) was then placed in position to verify the proper angulation of the gingival zenith. The high-value achromatic enamel CR Pearl Frost (Vit-l-escence) was applied to the in-

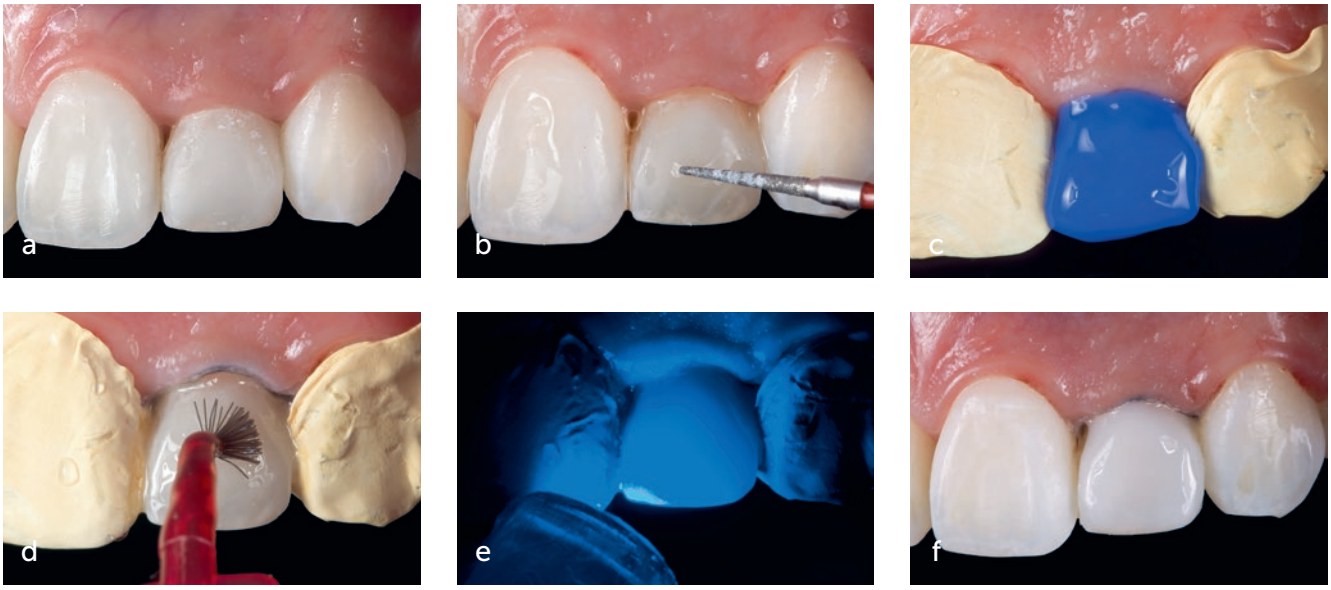

Fig 5 Restoration sequence of the dentin layer on the maxillary left lateral incisor. (a) Initial situation. (b) Minimally invasive preparation. (c) Application of phosphoric acid. (d) Application of universal adhesive with a Spiral Mix tip (Ultradent). (e) Photoactivation. (f) First layer of the CR to opacify the darkened substrate.

ner surface of the Uveneer template, which was placed over the tooth and pressed until the excess resin overflowed. The excess was removed with a thin interproximal carver (CVIPC; Hu-Friedy). Simultaneously, the CR was adjusted to adapt to the interproximal areas where the template did not embrace the tooth before photoactivation, which was then performed for 20 s on the facial surface (Valo). Once the CR was photopolymerized, the template was easily removed to begin the finishing and polishing steps (Fig 4a to c).

Technique 2: Conventional dentin stratification, masking of darkened tooth and use of Uveneer in the final layer of enamel

Once the restorative procedure on the maxillary right lateral incisor was complete, the template fit was tested in the maxillary left lateral incisor to determine the appropriate template size, and the adaptation in the cervical region was checked. A minimally invasive preparation was performed in the maxillary left lateral incisor (Fig 5a and b) in the same way as that previously described for the maxillary right lateral incisor. This was followed by acid etching (Fig 5c) and adhesive application (Fig 5d and e). A highly opaque and high-value CR was chosen (Fig 5f), which differed from the restorative technique performed on the maxillary right lateral incisor. A thicker first layer of A1-shade 'dentin' CR (Vit-l-escence) was applied directly onto the tooth surface to mask the darkened substrate, following by light curing (Fig 6a). This layer was extended from the cervical to the incisal region until proper adaptation and sculpture were obtained. Then, orange and blue pigments (Kolor + Plus) were applied to the cervical and incisal regions, respectively. In addition, an opaque white pigment was applied over the region corresponding to the opaque halo (Fig 6b).

Thereafter, the template was once again placed in position to check the proper angulation of the gingival zenith (Fig 6c). Pearl Frost was applied to the inner surface of the Uveneer template, which was placed over

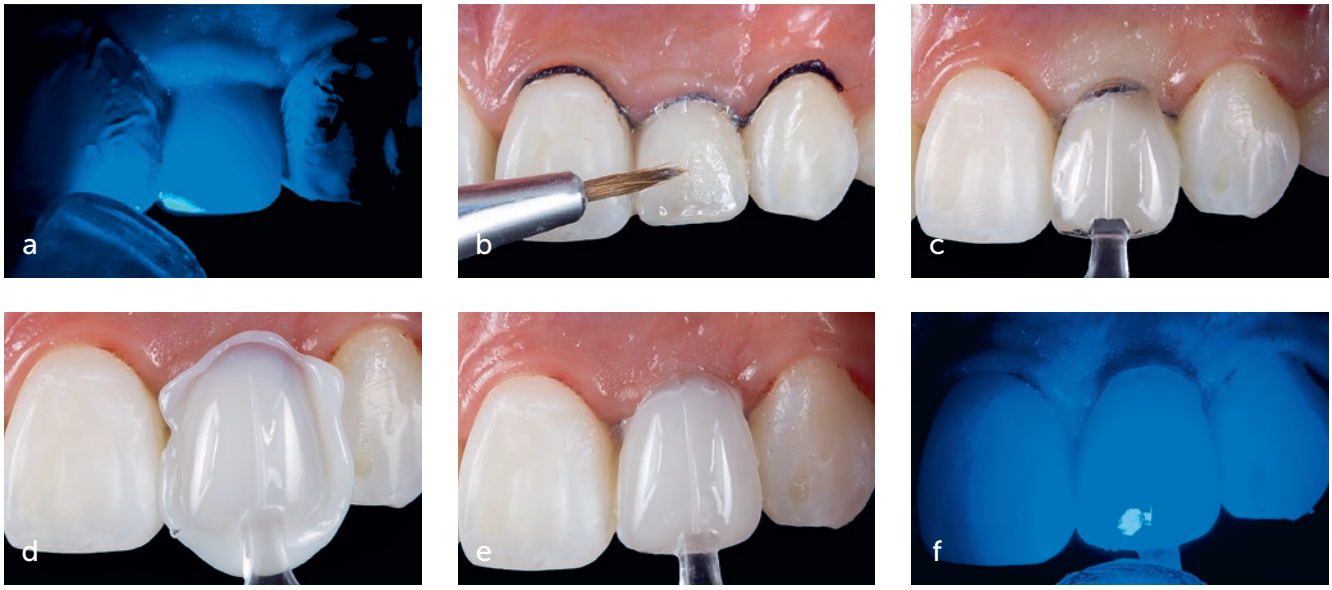

Fig 6 Tooth-restoration sequence of the enamel on the maxillary left lateral incisor. (a) Photoactivation of the dentin layer. (b) Fine brush for the application of a pigment in the dentin layer. (c) Test of the final template fit in the tooth (Uveneer, size L). (d) Complete pressing of the template without creating voids. (e) Excess removal. (f) Photoactivation of the enamel layer.

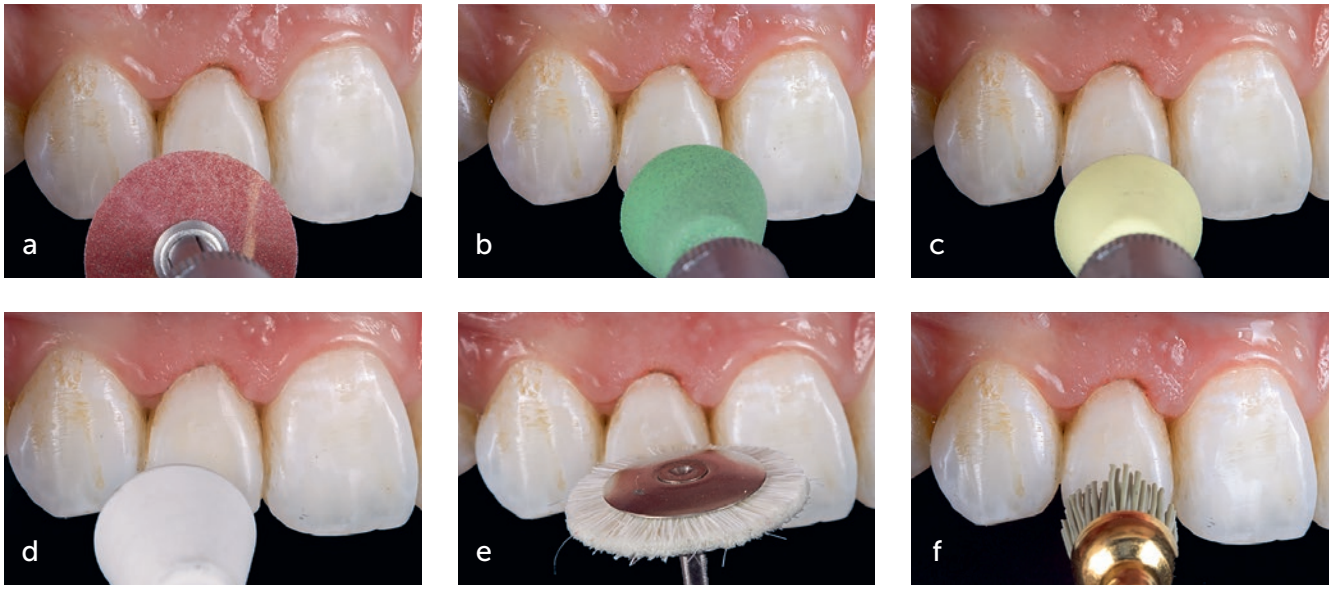

Fig 7 (a to f) Finishing and polishing steps, starting with a Sof-Lex disc with high granulation, followed by the use of silicon polishing discs with abrasive particles in descending abrasiveness. The case procedure was finished with brushes to obtain gloss.

the tooth and pressed until the excess resin overflowed (Fig 6d), and the excess was removed with a thin interproximal carver (CVI-PC) (Fig 6e). Similar to what was done in the maxillary right lateral incisor, the CR was adjusted to adapt to the interproximal areas where the template did not embrace the tooth before photoactivation, which was then performed for 20 s on the facial surface (Valo). Once the CR was photopoly-

merized (Fig 6f), the template was easily removed to begin the finishing and polishing steps (Fig 7a to f).

Finishing and polishing

The excess CR was removed using a No. 12 scalpel blade and interproximal finishing strips (Sof-Lex). Oral hygiene instructions were given to the patient, with the emphasis on using dental floss in the interproximal region and tooth brushing at least three times a day. The tooth grooves and primary anatomy of the lateral incisors were created using a multi-laminate bur (KG Sorensen) to match the characteristics of the surrounding teeth. After 1 week, the patient returned for restoration polishing, which was first performed with polishing discs (Sof-Lex), then silicone finishing and polishing tips (Jiffy; Ultradent) and polishing paste (Diamond Polish; Ultradent) (Fig 7). The immediate final extraoral and intraoral views are shown in Figure 8, and the clinical 1-year follow-up is shown in Figure 9.

Discussion

Since the introduction of veneers in the 1930s by Dr Pincus, techniques for the veneering of anterior teeth have successfully evolved so that today satisfactory and long-lasting restorations can be created.[8] In addition, adhesive technology has resulted in several advantages to modern dentistry. Less-invasive procedures can be performed with highly promising results.

The use of prefabricated templates for veneers fits within this context, once the pieces can be adapted with little wear to the tooth structure, so that part of the enamel structure is preserved. In some scenarios in which teeth are not darkened or are palatalized so there is enough space on the labial surface, the tooth-preparation step can be avoided. One of the manufacturer's indications is to bond resin veneer on enamel. This might be advantageous, since enamel is a highly reliable substrate for adhesion longevity[16] due to its inherent characteristics such as a high amount of minerals and a lack of fluids.

In addition to the advantages of the bonding technique, minimally invasive preparations present biomechanical advantages. In 1994, Reeh and Ross[17] demonstrated by a finite element test and strain gauge sensors that the loss of facial enamel in preparations for veneers decreases tooth stiffness by approximately 70%. Further studies[18,19] have corroborated this finding, and have indicated that tooth stiffness can be recovered to 100% by ceramic veneering, and to nearly 83% by CRs.[17] In minimally invasive preparations, such as the one performed in this case report, this drawback is prevented because a minimally invasive preparation with a finishing line was only performed to avoid emergency profiles with inadequate thicknesses.

When compared with the first prefabricated systems launched onto the market in the mid-1970s (Mastic; Caulk), the system used in this case report presents some advantages.[20,21] Mastic had undesirable results due to the technological limitations of restorative materials and adhesive technology at the time. Mastic's composition (methylmethacrylate matrix and large glass fillers) gave it a poor surface quality, which compromised its appearance.[22]

New systems recently launched onto the market (Componeers; Colténe Whaledent and Edelweiss; Edelweiss Dentistry Products) benefit from all the improvements that current bonding techniques and restorative materials present (better mechanical properties and long-lasting bonding). However, these new systems preserve the initial concept of prefabricated veneers because they still use prefabricated 'shells' to cover the tooth. The template system used

Fig 8 Case finished after the finishing and polishing sequence. (a) Extraoral smile. (b and c) Intraoral views of the final situation.

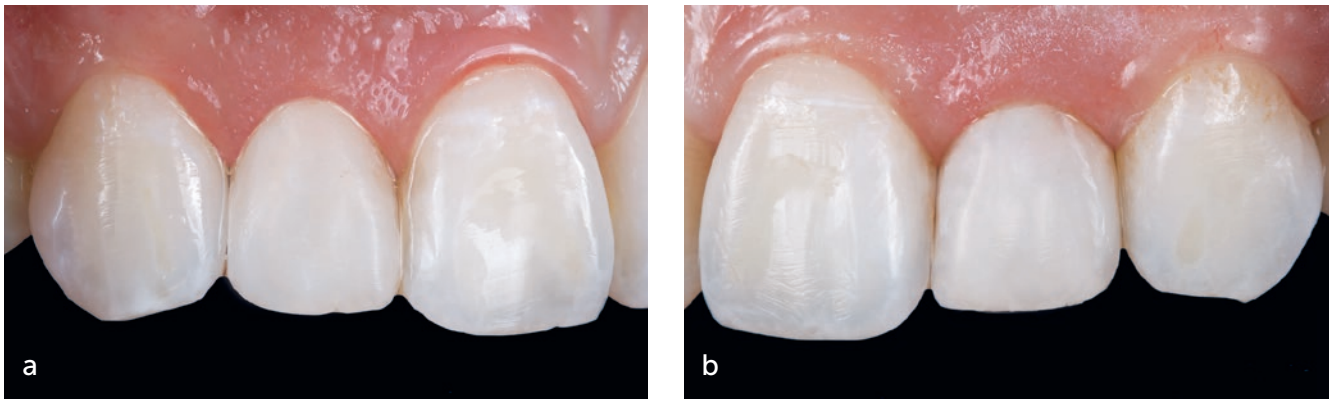

Fig 9 (a and b) Intraoral views of the direct restorations using templates at the 1-year follow-up. No pigmentation or signs of gingival inflammation and adaptation can be seen. The papilla adapted to the interproximal areas.

in this case report improves upon this concept by turning the veneers into templates that allow for the use of any kind of CR available on the market. This makes the obtained restoration more adaptable to any kind of available CR. Our speculation is that its long-term behavior should be similar to that expected with the freehand technique.

However, one of the limitations we found using prefabricated templates is the lack of control of thickness in the final layer, which may require some practice since it basically depends on the thickness left for material placement on the prepared tooth to provide a value outcome similar to that of the adjacent teeth. As in freehand techniques, we recommend that clinicians build up thicker dentin layers when rebuilding a darkened tooth or when using systems with achromatic enamel effects (eg, Vit-l-scence), so that the enamel layer can be as thin as possible. The use of pigments also results in

natural-looking restorations, as pigments imitate translucency and saturation (depending on the region to be restored).

Although dental ceramics continue to be the gold standard,[8] the use of CRs still represents a cheaper alternative for patients.[23] In this sense, the prefabricated template system combines some advantages of both techniques, allowing easier sculpting to reestablish tooth anatomy compared with conventional restorative techniques. In addition, the inner surface of the prefabricated templates (Uveneer) provides a highly smooth composite surface. This could be considered an advantage when compared with conventional techniques that use CRs, as the smoother and more polished resin surfaces will contribute to the maintenance of brightness over time. Moreover, this procedure reduces the chair time needed, as the polishing steps require less effort to provide a highly polished composite surface. However, additional follow-up studies are required to confirm this hypothesis.

In 2011, Dietschi and Devigus[24] described a similar system for direct veneering. In that case report, the prefabricated Edelweiss veneers were presented as an alternative to freehand built-up CR veneers. The system offers prepolymerized veneers in many sizes and a highly glossy facial surface obtained by laser treatment to facilitate finishing and polishing. However, this feature has many limitations. As standardized sizes might be adjusted in most cases to improve the gingival contour, emergence profile, and shape of the restored tooth (mainly in cervical and interproximal regions), this might be a limitation for prepolymerized systems, since one of the manufacturer's recommendations is to avoid polishing the glossy facial surface to maintain a highly polished surface over time. Therefore, the template system used in this clinical report seems to be more versatile for these scenarios, as the CR is the same as that used in the freehand technique. However, even though the templates allow for easier adaptation in the cervical region, the adaptation in the interproximal areas requires attention due to the embracement area of the template that in some cases cannot entirely cover the interproximal faces. In order to achieve better adaptation in these regions, we recommend the use of interproximal instruments to allow for proper adaptation prior to photoactivation.

One interesting difference between these templates and other prefabricated veneer systems such as Componeers or Edelweiss is that they allow the final enamel layer shade to be chosen, which makes esthetic results more predictable, mainly when single veneers are built up. In these cases, the system may allow the clinician to make a previous mock-up without a bonding procedure on the prepared tooth, allowing for an accurate preview of the final restoration. Studies have shown decreased tensile bonding strength values in bleached teeth when adhesive procedures were performed immediately after bleaching.[25,26] In the present case, all adhesive procedures were performed over 2 weeks after tooth bleaching, so the bonding properties were not compromised,[27] and the tooth shade was stable. As a consequence, any possible false positive esthetic results due to the dehydration or acidity of the bleaching system used were prevented.[28-31] An alternative for a situation that requires the use of veneers after a shorter time interval between bleaching and restorative procedures could be the use of 10% sodium ascorbate gels, as described by Kaya and Türkün in 2007.[32]

After 1-year follow-up, the restored teeth had a good clinical aspect, with no signs of gingival inflammation, thus confirming the correct gingival contour (Fig 9). Studies have demonstrated that the survival of anterior restorations is more dependent on patient caries risk and parafunctional habits

than on the type of CR used.[33] In this case report, the use of templates did not influence the behavior of the restorations over time. Therefore, it is expected that using templates may be a reliable technique for veneer placement without compromising long-term survival.

Conclusion

The results obtained with prefabricated templates for CR veneers can be improved with simple stratification techniques. They are an easy-to-use and cost-effective alternative for solving esthetic problems in anterior teeth.

References

1. Tin-Oo MM, Saddki N, Hassan N. Factors influencing patient satisfaction with dental appearance and treatments they desire to improve aesthetics. BMC Oral Health 2011;11:6.
2. Blank JT. Simplified techniques for the placement of stratified polychromatic anterior and posterior direct composite restorations. Compend Contin Educ Dent 2003;24(2 suppl):19–25.
3. Morita RK, Hayashida MF, Pupo YM, Berger G, Reggiani RD, Betiol EA. Minimally Invasive Laminate Veneers: Clinical Aspects in Treatment Planning and Cementation Procedures. Case Rep Dent 2016;2016:1839793.
4. Haywood VB. Historical development of whiteners: clinical safety and efficacy. Dent Update 1997;24:98–104.
5. Pini NI, Sundfeld-Neto D, Aguiar FH, et al. Enamel microabrasion: An overview of clinical and scientific considerations. World J Clin Cases 2015;3:34–41.
6. Dietschi D. Free-hand bonding in the esthetic treatment of anterior teeth: creating the illusion. J Esthet Dent 1997;9:156–164.
7. Rochette AL. A ceramic restoration bonded by etched enamel and resin for fractured incisors. J Prosthet Dent 1975;33:287–293.
8. Calamia JR, Calamia CS. Porcelain laminate veneers: reasons for 25 years of success. Dent Clin North Am 2007;51: 399–417.
9. Beier US, Dumfahrt H. Longevity of silicate ceramic restorations. Quintessence Int 2014;45:637–644.
10. Sabatini C, Guzmán-Armstrong S. A conservative treatment for amelogenesis imperfecta with direct resin composite restorations: a case report. J Esthet Restor Dent 2009;21:161–169.
11. Korkut B, Yanikoğlu F, Günday M. Direct composite laminate veneers: three case reports. J Dent Res Dent Clin Dent Prospects 2013;7:105–111.
12. Pontons-Melo JC, Pizzatto E, Furuse AY, Mondelli J. A conservative approach for restoring anterior guidance: a case report. J Esthet Restor Dent 2012;24:171–182.
13. Denehy GE. A direct approach to restore anterior teeth. Am J Dent 2000;13(spec no):55D–59D.
14. Demarco FF, Collares K, Correa MB, Cenci MS, Moraes RR, Opdam NJ. Should my composite restorations last forever? Why are they failing? Braz Oral Res 2017;31(suppl 1):e56.
15. Melo MA, Moysés MR, Santos SG, Alcântara CE, Ribeiro JC. Effects of different surface treatments and accelerated artificial aging on the bond strength of composite resin repairs. Braz Oral Res 2011;25: 485–491.
16. Loguercio AD, Moura SK, Pellizzaro A, et al. Durability of enamel bonding using two-step self-etch systems on ground and unground enamel. Oper Dent 2008;33: 79–88.
17. Reeh ES, Ross GK. Tooth stiffness with composite veneers: a strain gauge and finite element evaluation. Dent Mater 1994;10: 247–252.
18. Magne P, Kwon KR, Belser UC, Hodges JS, Douglas WH. Crack propensity of porcelain laminate veneers: A simulated operatory evaluation. J Prosthet Dent 1999;81:327–334.
19. Magne P, Magne M, Belser UC. Adhesive restorations, centric relation, and the Dahl principle: minimally invasive approaches to localized anterior tooth erosion. Eur J Esthet Dent 2007;2:260–273.
20. Haas BR. Mastique veneers: a cosmetic and financial alternative in post-periodontal care. J N J Dent Assoc 1982;53:25–27.
21. Helpin ML, Fleming JE. Laboratory technique for the laminate veneer restoration. Pediatr Dent 1982;4:48–50.
22. Jensen OE, Soltys JL. Six months clinical evaluation of prefabricated veneer restorations after partial enamel removal. J Oral Rehabil 1986;13:49–55.
23. Pontons-Melo JC, Furuse AY, Mondelli J. A direct composite resin stratification technique for restoration of the smile. Quintessence Int 2011;42:205–211.
24. Dietschi D, Devigus A. Prefabricated composite veneers: historical perspectives, indications and clinical application. Eur J Esthet Dent 2011;6:178–187.
25. Toko T, Hisamitsu H. Shear bond strength of composite resin to unbleached and bleached human dentine. Asian J Aesthet Dent 1993;1:33–36.
26. Dishman MV, Covey DA, Baughan LW. The effects of peroxide bleaching on composite to enamel bond strength. Dent Mater 1994;10:33–36.
27. Cavalli V, Reis AF, Giannini M, Ambrosano GM. The effect of elapsed time following bleaching on enamel bond strength of resin composite. Oper Dent 2001;26:597–602.
28. Tay LY, Kose C, Herrera DR, Reis A, Loguercio AD. Long-term efficacy of in-office and at-home bleaching: a 2-year double-blind randomized clinical trial. Am J Dent 2012;25:199–204.

29. Bernardon JK, Sartori N, Ballarin A, Perdigão J, Lopes GC, Baratieri LN. Clinical performance of vital bleaching techniques. Oper Dent 2010;35:3–10.
30. Strobl A, Gutknecht N, Franzen R, Hilgers RD, Lampert F, Meister J. Laser-assisted in-office bleaching using a neodymium:yttrium-aluminum-garnet laser: an in vivo study. Lasers Med Sci 2010;25: 503–509.
31. Reis A, Dalanhol AP, Cunha TS, Kossatz S, Loguercio AD. Assessment of tooth sensitivity using a desensitizer before light-activated bleaching. Oper Dent 2011;36:12–17.
32. Kaya AD, Türkün M, Arici M. Reversal of compromised bonding in bleached enamel using antioxidant gel. Oper Dent 2008;33:441–447.
33. Demarco FF, Collares K, Coelho-de-Souza FH, et al. Anterior composite restorations: A systematic review on long-term survival and reasons for failure. Dent Mater 2015;31: 1214–1224.